Western Trauma Association Critical Decisions in Trauma: Management of parapneumonic effusion

Hunter B. Moore, MD, Ernest E. Moore, MD, Clay Cothren Burlew, MD, Frederick A. Moore, MD, Raul Coimbra, MD, James W. Davis, MD, Jason L. Sperry, MD, Robert C. McIntyre, Jr., MD, *and* **Walter L. Biffl, MD,** *Denver, Colorado*

Pleural infection associated with pneumonia is a potentially lethal disease afflicting more than 60,000 patients annually in the United States.[1,2] The incidence continues to rise,[2] and the mortality rate exceeds that of myocardial infarction.[3] Five thousand years ago, the Egyptian physician Imhotep first described pleural space disease,[4] and Hippocrates in 400 BC was credited for recognizing that prompt drainage of the infected pleural space is essential.[5] When these infections become loculated, they are no longer amenable to tube thoracostomy and operative decortication is required.[6–9] To understand the pathophysiology of a complicated parapneumonic effusion, it is instructive to review the anatomy of the pleural and cytologic players maintaining homeostasis in this unique space. The pleural cavity arises from the coelom that also forms the pericardium and peritoneum.[10] The pleural cavity is lined by mesothelial cells surrounded by a layer of connective tissue, macula cribiformis, which is then encased in two layers of elastic tissue. Visceral mesothelium is intricately connected to the lung parenchyma, whereas the parietal layer is more loosely connected to the thoracic structures separated by a variable fatty layer. The parietal pleura has specialized areas known as stoma, and an extensive lymphatic network exists below which is the predominant route of fluid resorption. Under normal conditions, it is estimated that each pleural cavity generates 0.2 to 0.4 mL/kg per hour.[11] The fluid originates predominantly from the parietal capillaries because of hydrostatic pressure, augmented by the negative pressure of the pleural space. Less fluid is produced by the visceral pleura because the hydrostatic pressure is attenuated by pulmonary venous drainage. However, the visceral surface will add more pleural fluid with increased pulmonary interstitial pressure. The capacity for pleural fluid absorption is thought to exceed 500 mL of fluid from each cavity with an intact lymphatic system. Thus, the net accumulation of pleural fluid is the result of a dynamic system of fluid production and absorption. Recent ultrasound studies of healthy individuals suggest that less than 4 mm of dependent pleural fluid should be considered normal.[12]

Complicated parapneumonic effusions, and ultimately empyemas, develop in three conceptual phases.[7–9] The early phase is a sterile effusion caused by parenchymal inflammation that activates mesothelial cells and enhances capillary permeability, termed exudative (days 2–5). This is thought to be driven by proinflammatory cytokines, including interleukin 8 and tumor necrosis factor-α.[8] Ultimately, the volume of fluid traversing into the pleural cavity exceeds the capacity to reabsorb the fluid and an effusion develops. The second phase is termed fibropurulent, which is initiated by bacterial infection (days 5–10). At this point, the immune system is activated and the once hypocoagulable environment is changed dramatically. Bacterial and neutrophil activity acidify the fluid, consume glucose, increase protein content, and release lactate dehydrogenase (LDH) from cellular apoptosis and necrosis. The environment now becomes hypercoagulable because of the integrated responses of the innate immune and coagulation systems.[13–15] These findings are directly relevant to the evolution of complicated effusions because the exuberant fibrin deposition is a concerted effort to control progressive infection. The final state of a complicated effusion is referred to as the organization phase (days 10–21). Fibroblasts migrate into the pleural space and create a dense fibrotic lining of the visceral and parietal surfaces. This phase is thought to be driven by regenerative cytokines, for example, transforming growth factor-β and platelet-derived growth factor released primarily from activated mesothelial cells.[8,16] The net result is a progressive rind that encases the lung, reducing ventilatory capacity and sequestering bacteria.[6–9]

The objective of this management algorithm for parapneumonic fluid collections (Fig. 1) is to outline cost-effective diagnostic and therapeutic interventions in the surgical intensive care unit (SICU) based on the pathologic state of the pleural cavity. These guidelines are derived from the published experience with adult populations, but conceptually, the same principles apply to the pediatric age group.[17–20]

A. The standard method to estimate the amount of pleural fluid has been the lateral decubitus chest roentgenogram. Recent comparative studies indicate that ultrasound is a more reliable method to quantitate a pleural effusion.[21–25] This is a grade A recommendation. As previously mentioned, an effusion measured up to 4 mm is considered

Submitted: February 17, 2012; Accepted: April 26, 2012, Published online: August 17, 2012.

From the Department of Surgery, Denver Health Medical Center/University of Colorado (H.B.M., E.E.M., C.C.B., R.C.M., W.L.B.), Denver, Colorado; Department of Surgery, University of Florida (F.A.M.), Gainesville, Florida; Department of Surgery, University of California (R.C.), San Diego, California; Department of Surgery, University of California (J.W.D), Fresno, California; and Department of Surgery, University of Pittsburgh (J.L.S.), Pittsburgh, Pennsylvania.

Presented at the 42nd Annual Meeting, Western Trauma Association, Vail, Colorado, in March 2012.

Address for reprints: Ernest E. Moore, MD, The Journal of Trauma and Acute Care Surgery, 655 Broadway, Suite 365, Denver, CO 80203; email: ernest.moore@dhha.org.

DOI: 10.1097/TA.0b013e31825ff7e4

Copyright © 2012 Lippincott Williams & Wilkins. Unauthorized reproduction of this article is prohibited.

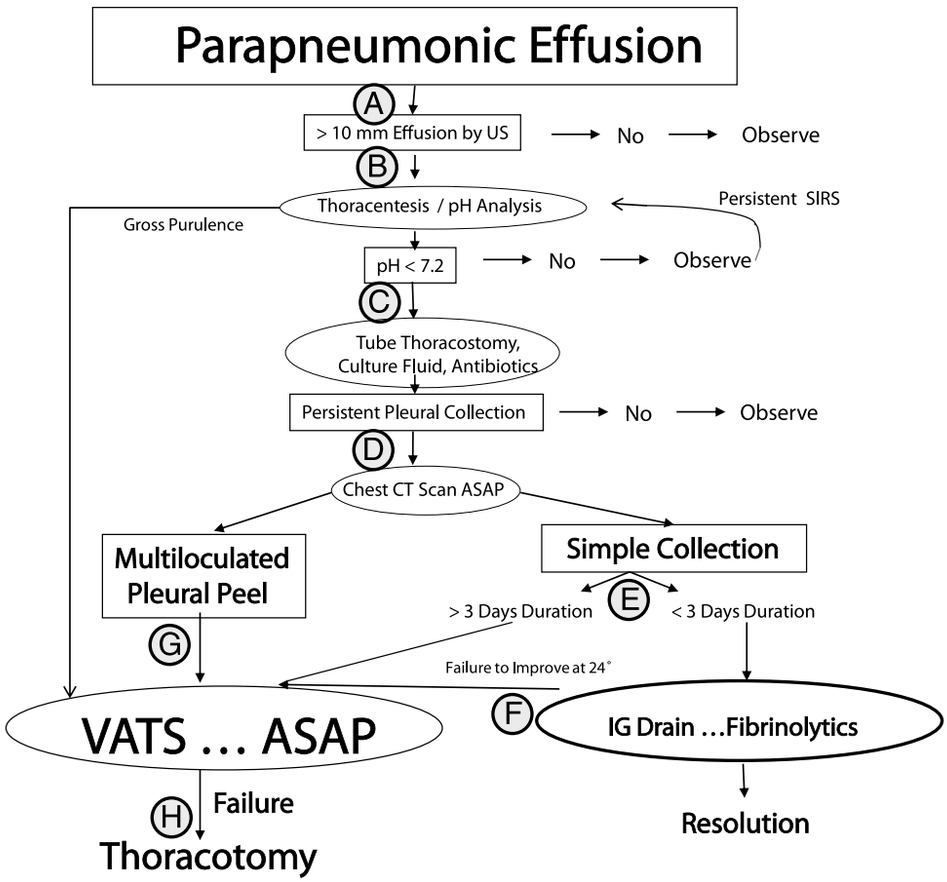

Figure 1. Management algorithm for parapneumonic effusion.

normal.[12] Furthermore, an effusion is expected to accompany severe pneumonia.[7–9] Clinical studies by Light et al.[26] indicated that infections involving an effusion of less than 10 mm will resolve with antibiotics alone, and this has been supported by subsequent series.[27,28] This is a level I prognostic evidence. Consequently, ultrasonography-guided thoracentesis is recommended for effusions greater than 10 mm. This is a grade B recommendation.

B. Gross purulence (empyema) evident at the time of thoracentesis is unusual but constitutes an indication for prompt video-assisted thoracoscopic surgery (VATS) decortication.[7] In all other circumstances, the pleural fluid should be submitted for laboratory analysis. A common oversight in the SICU is to pursue the distinction of an exudative versus transudative effusion, that is, via Light's criteria: protein greater than 0.5 serum, LDH greater than 0.6 serum, or LDH greater than two-thirds normal serum.[29] But the critical issue is whether the parapneumonic fluid collection is infected, and most of the pleural collections in the SICU are exudative. The most cost-effective means to analyze this is to measure the pH of the pleural fluid using a standard blood gas analyzer, available in most SICUs. A pH less than 7.2 is the threshold, although less than 7.3 is considered high risk.[4,7–9,30–34] This is a level I diagnostic evidence. A notable exception is a *Proteus* infection where the pH may exceed 7.4 because of ammonia production.[8] An alternative diagnostic criterion is a pleural fluid glucose less than 60 mg/dL when infection is suspected.[3] This is a level I diagnostic evidence. Because the evolution of an empyema may extend for days to weeks and the early phase is a sterile effusion, a repeat diagnostic thoracentesis should be done in any patient with a persistent unexplained systemic inflammatory response syndrome and unilateral pleural effusion.[7–9]

C. A pleural pH less than 7.2 (or glucose <60 mg/dL) is diagnostic of infection and warrants prompt tube thoracostomy. The optimal size of the chest tube remains debated,[3,35,36] but a guide wire inserted 18F seems effective in removing this hypercoaguable fluid. This is a grade B recommendation. These smaller chest tubes are associated with less chest wall pain than blunt dissection–inserted tubes, without compromise in clinical outcome. The position of the chest tube, however, is important.[35] The tube should be placed in the posterior (dependent) pleural space and not within a pulmonary fissure. We have observed that the typical "trauma" chest tube[37] introduced through the fifth intercostal space (ICS), at the mid–clavicular line, favors fissure

Copyright © 2012 Lippincott Williams & Wilkins. Unauthorized reproduction of this article is prohibited.

placement. Consequently, we recommend ultrasonography-guided tube insertion via the sixth ICS. But this is based on our unpublished experience (level V therapeutic evidence). A Gram stain and culture of the pleural fluid should be obtained at the time of tube thoracostomy to differentiate the organism, although 20% to 40% of the time, there is no reported identifiable pathogen.[38–42] More recent techniques such as countercurrent electrophoresis, latex agglutination, or bacterial DNA detection by polymerase chain reaction should improve pathogen identification.[9] This is currently a grade C recommendation. The most comprehensive prospective analysis of bacteria in empyema is the United Kingdom Multicenter Intrapleural Sepsis Trial (MIST I).[40,41] In empyema associated with community-acquired pneumonia, the most common pathogen (Table 1) was *Streptococcus milleri* (32%), whereas if hospital acquired, it was methicillin-resistant *Staphylococcus aureus* (28%). Patient characteristics, including diabetes, alcoholism, age older than 60 years, and trauma are associated with more anaerobic and resistant gram-positive organisms.[37,38] Hospital-acquired empyema is reported to have a fourfold greater risk of death compared with community acquired.[39] The relatively poor outcome with *S. milleri* is postulated because of the frequent presence of anaerobes.[43,44] Thus, presumptive antibiotics should be based on the type of pneumonia (community vs. hospital acquired), the pathogens identified in the antecedent pneumonia, and patient comorbidities.[38–44] Of note, although most antibiotics penetrate the pleura well, aminoglycosides may be inactivated at a lower pH.[45]

D. Pleural collections persisting for more than 24 hours after adequate tube thoracostomy, confirmed by ultrasonography, warrant prompt computed tomographic (CT) imaging for evaluation of the entire thoracic space.[16,29] This is diagnostic level II evidence. Delay in diagnosis of an undrained simple fluid collection allows progression to a complex multilocular process and the final organization stage.[46] As Sahn and Light[28] stated in 1989, "the sun should never set on a parapneumonic effusion"; early diagnosis and treatment of complicated pleural infection is essential for optimal outcomes. CT images are crucial for the next step in the management of pleural space infections that have not resolved with tube drainage.[4,16,29,46] This is a grade B recommendation.

TABLE 1. Bacteriology of Parapneumonic Empyema According to MIST I

Community Acquired		Hospital Acquired	
S. milleri	32%	Methicillin-resistant *Staphylococcus aureus*	28%
Anaerobes	16%	Other staphylococci	18%
Streptococcus pneumonia	13%	Enterobacteriacea	16%
Staphylococci	11%	Enterococci	13%
Enterobacteriacea	7%	Anaerobes	5%
Other streptococci	7%	*Pseudomonas*	5%
Haemophilus influenzae	3%	*S. milleri*	5%
Proteus	3%	Other streptococci	5%

E. Early recognition of a persistent pleural collection (<3 days) offers the potential to use fibrinolytics to release the trapped fluid via a chest tube. Although conceptually intuitive considering the pathophysiology of empyema, fibrinolytic therapy remains controversial. The first report of fibrinolytic therapy in the pleural space was by Tillett and Sherry[47] in 1949. They infused purified hemolytic streptococcal concentrates, presumed to contain streptokinase and deoxyribonuclease (DNase). Although apparently safe, there was no documented improvement in patient outcome during the ensuing 60 years. The first randomized trial, by Davies et al.[48] in 1997, demonstrated radiographic improvement in 24 patients but no discernable clinical benefit. This was followed by a number of underpowered randomized studies in Europe, suggesting that urokinase demonstrated a therapeutic value.[49–51] These conflicting results led to the MIST I study,[41] involving 52 hospitals in the United Kingdom with 412 randomized patients. The data indicated that 72 hours of streptokinase treatment resulted in no improvement in mortality, rate of surgery, or length of stay and was associated with an increased rate of serious adverse events. This study was criticized for including a heterogeneous mix of patients with different comorbidities and different stages of pleural disease.[52] The most recent Cochrane review in 2009[6] noted that there was a discordance between earlier studies and the MIST I data and concluded that fibrinolytics should be used selectively because there has not been a proven benefit in high-quality trials; however, the authors acknowledged that there may be certain subgroups of patients who benefit from this therapy. Clinical studies in other arenas indicated that tissue plasminogen activator (tPA) was a more effective and safer agent than streptokinase or urokinase as a fibrinolytic agent.[53] Other studies suggested that the addition of DNase to streptokinase improves evacuation of an empyema.[54,55] Subsequently, MIST II, using tPA with or without DNase, has been completed.[56] Unfortunately, this study (n = 210; four study groups) was only powered sufficiently to evaluate radiographic changes.[57] But consistent with MIST I, tPA showed no benefit over no fibrinolytic treatment. This is level I therapeutic evidence. The combination of tPA and DNase, however, was beneficial in both the primary end point (radiographic clearance) and secondary end points (need for thoracotomy, hospital length of stay). The authors responsibly conclude, "Our study shows that combination intrapleural t-PA and DNAse therapy improves the drainage of pleural fluid in patients with pleural infection …. This combined treatment may therefore be useful in patients in whom standard medical management has failed and thoracic surgery is not a treatment option. However, appropriate trials are needed to accurately define the treatment effects."

Thus, the debate continues regarding the role of fibrinolytics in the management of pleural collections.

© 2012 Lippincott Williams & Wilkins

Copyright © 2012 Lippincott Williams & Wilkins. Unauthorized reproduction of this article is prohibited.

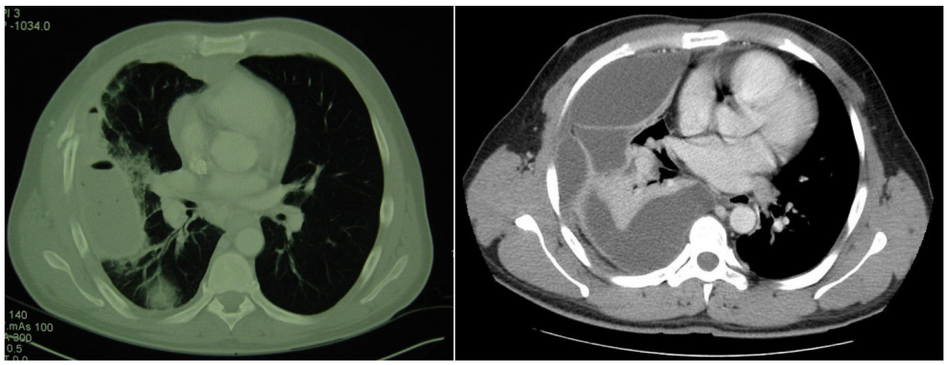

Figure 2. CT imaging distinguishes a simple pleural collection (*left*) that may respond to fibrinolytic therapy versus a complex pleural collection that warrants prompt VATS.

Most intensivists have observed effective eradication of early empyema in some patients but agree that the appropriate population remains ill defined. On the basis of the pathophysiology of empyema and the morbidity of thoracotomy for delayed intervention, most think that fibrinolytic treatment should be attempted for early empyema with simple collections separated by thin septa documented by CT scan (Fig. 2) if tube thoracotomy drainage fails. Image-guided direct infusion of fibrinolytics into the collection is superior to delivery via the failed chest tube. The precise agent, dosage, and timing of infusion remain to be analyzed; the combination of tPA and DNase seems to be the most effective regimen at this time.[56]

F. A critical decision is to acknowledge failure of fibrinolytic therapy in favor of VATS evacuation. In general, collections that do not have substantial improvement after 24 hours of fibrinolytic infusion should undergo prompt VATS to avoid the need for thoracotomy.[7,8,58,59] This is a grade C recommendation.

G. Multiloculated empyemas with an established pleural peel evident on CT scanning (Fig. 2) should undergo prompt VATS.[6] Although "medical" VATS using local anesthesia has been reported,[60] the standard procedure is lateral decubitus positioning with dual lung ventilation to facilitate comprehensive evaluation of the involved pleural cavity and systematic decortication.[61] A key maneuver is to enter the pleural space without injuring the underlying lung because of extensive pleural adhesions. An initial incision in the upper thorax, where the empyema is least developed, is usually the safest strategy. In most cases, we have used the existing chest tube site to free the lung for placement of the initial port (Fig. 3). With the thorascope in position and the lung at least partially deflated, additional working ports are added under direct vision (Fig. 4). The sites for these

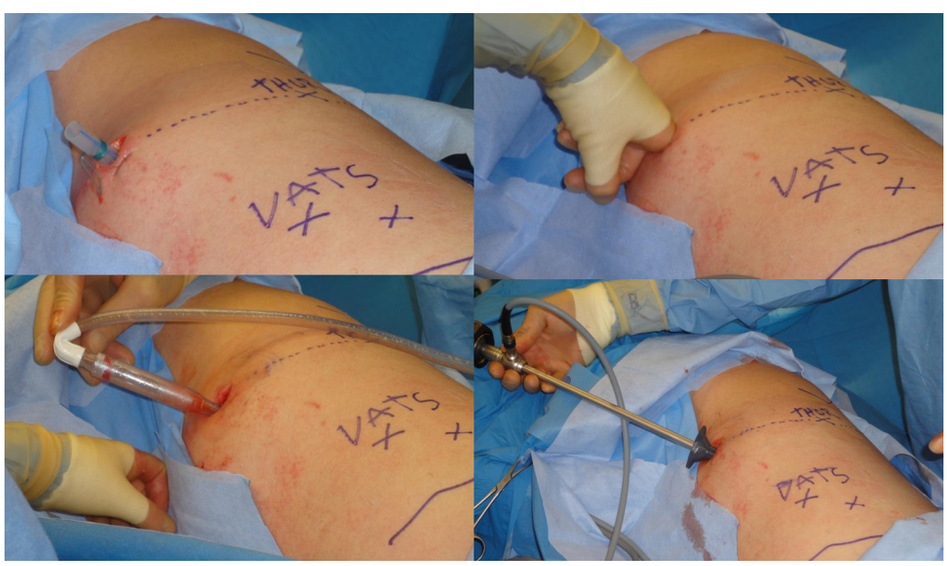

Figure 3. In performing VATS, the thoracic cavity must be entered carefully to avoid tearing the lung because of firm adhesions. We prefer to use the existing chest tube site, digitally mobilizing the adherent lung and further opening a space for the thoracoscope with a large blunt suction tip.

Copyright © 2012 Lippincott Williams & Wilkins. Unauthorized reproduction of this article is prohibited.

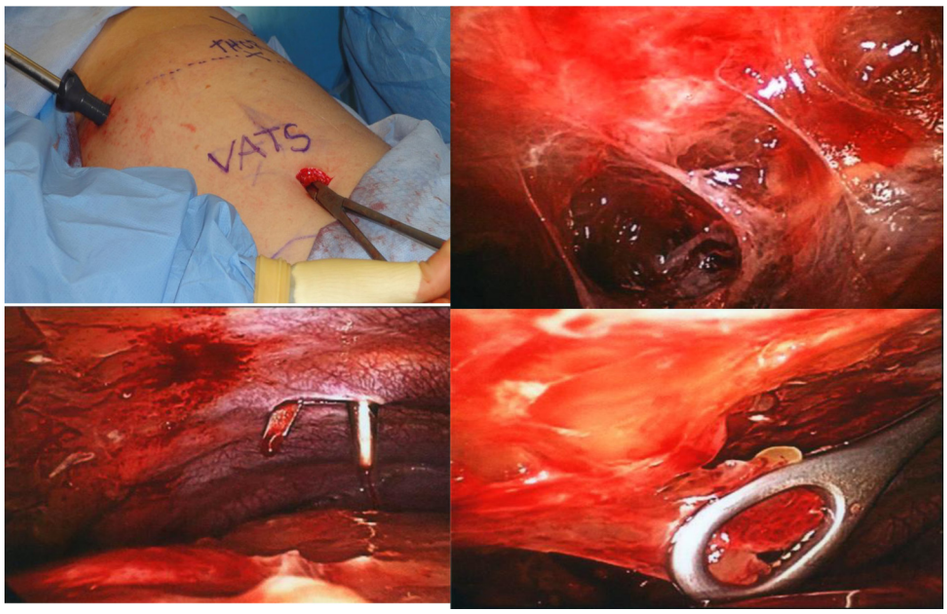

Figure 4. After successful introduction of the thoracoscope, additional port sites are added at the anticipated locations for subsequent tube thoracostomies. Usually, the decortication can be achieved with ringed forceps.

ports are chosen to match the chest wall entrance of the chest tubes after VATS (Fig. 5). The objectives of VATS are to unroof all loculated collections, including those in the fissures, and to free the lung of the visceral pleural fibrous encasement. Usually, the decortication is initiated in the upper lobe, where the process is more limited, and ultimately, the fibrous debris is removed as much as possible from the lung surface to enable reexpansion. Dissection must be done carefully on the mediastinal side to avoid injury to the phrenic nerve and pulmonary vasculature. Similarly, clearing the diaphragm must be done cautiously to avoid perforation. In fact, the diaphragm does not need to be systematically debrided as long as the lower lobe is freed. After extensive decortication, the thorax is usually drained with three relatively large chest tubes (28F) to facilitate

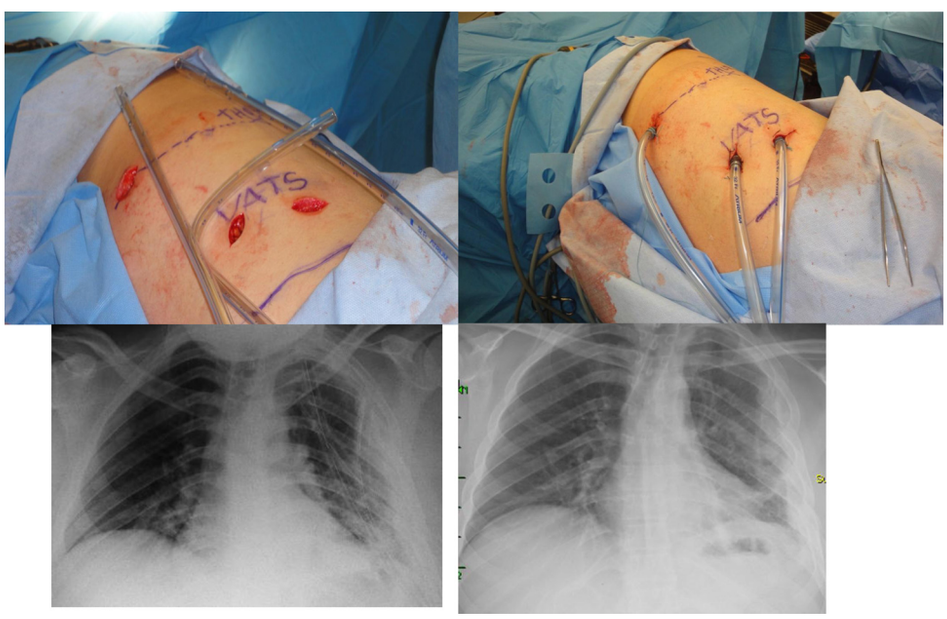

Figure 5. With advanced empyemas, we usually place three relatively large chest tubes; 28F anterior, posterior, and angled above the diaphragm. The chest roentgenogram (*left*) illustrates the three tube thoracostomies and the follow-up examination at day 6 after sequential removal of the tubes.

© 2012 Lippincott Williams & Wilkins

Copyright © 2012 Lippincott Williams & Wilkins. Unauthorized reproduction of this article is prohibited.

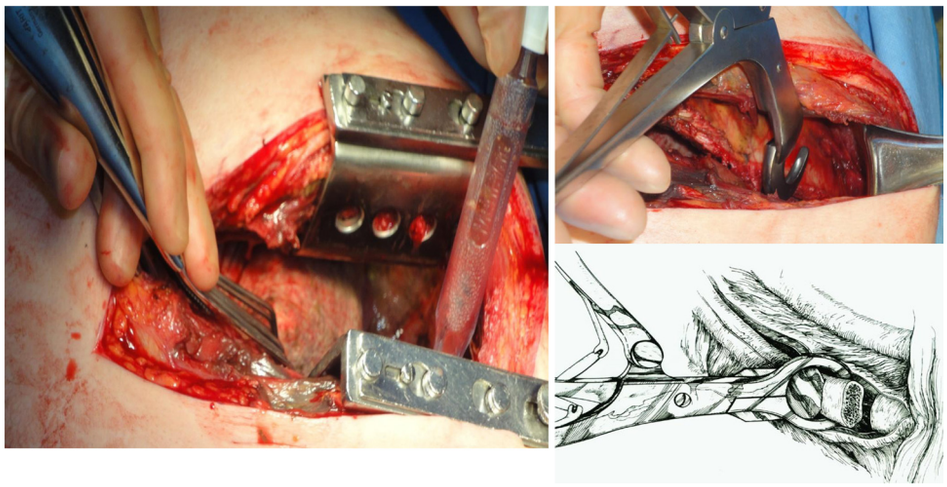

Figure 6. In the event that VATS is not feasible because of dense adhesions, a limited muscle-sparing thoracotomy is perfomed. Transecting the posterior rib facilitates exposure of the fibrous cavity.

removal of debris and blood associated with the procedure (Fig. 5). The most inferior tube is usually an angled tube positioned in the posterior dependent recess of the chest.

H. In the event of a dense fibrous peel that precludes clearance via VATS, a limited lateral muscle-sparing thoracotomy ("mini thoracotomy") is performed to accomplish decortication (Fig. 6). Transecting the posterior rib facilitates exposure of the fibrous cavity. Advanced empyemas often require scalpel incision to free the lung for reexpansion; inspection of the lung with periodic reinflation should be done to avoid extensive pulmonary parenchymal air leaks. In the unusual case of a chronic empyema, a standard posterolateral thoracotomy is required. Often, the safest approach is to develop an extrapleural plane and directly enter the empyema cavity before any further thoracic dissection is done. After these extensive decortications, the thorax is drained with three relatively large chest tubes (28F), and the most inferior tube is usually an angled tube positioned in the posterior dependent recess of the chest. Occasionally, these tubes are simply transected to provide external drainage for outpatient management of extended processes.

Treatment of an advanced process caused by a necrotic infected lung with associated major air leaks in a severely immunocompromised patient warrants open thoracic drainage. The Eloesser flap, thoracic cavity marsupialization via segmental rib resection and suturing the skin to the underlying parietal surface (Fig. 7), has been the standard for these complicated cases.[62] But recently, simple open drainage with suturing the skin margin to the chest wall, thoracostoma, and the application of a vacuum-assisted wound closure have been popularized.[63–65] Ultimately, some of these wounds will heal by secondary intention, and the remaining can be closed with thoracomyoplasty.[66,67]

Figure 7. This patient underwent an Eloesser flap open thoracostomy for an advanced complex parapneumonic empyema with a large pulmonary abscess.

AUTHORSHIP

H.B.M. and E.E.M. wrote this manuscript. All authors read, critically discussed, and approved of the final article for publication.

DISCLAIMER

The Western Trauma Association (WTA) develops algorithms to provide guidance and recommendations for particular practice areas but does not establish the standard of care. The WTA develops algorithms based on the evidence available in the literature and the expert opinion of the task force in the recent time frame of the publication. The WTA considers the use of the algorithms to be voluntary. The ultimate determination regarding their application is to be made by the treating physician and health care professionals, with full consideration of the individual patient's clinical status and available institutional resources, and is not intended to take the place of health care providers' judgment in diagnosing and treating particular patients.

DISCLOSURE

The authors declare no conflicts of interest.

REFERENCES

1. Sahn SA. Management of complicated parapneumonic effusions. *Am Rev Respir Dis*. 1993;148:813–817.

Copyright © 2012 Lippincott Williams & Wilkins. Unauthorized reproduction of this article is prohibited.

2. Grijalva CG, Zhu Y, Nuorti JP, Griffin MR. Emergence of parapneumonic empyema in the USA. *Thorax*. 2011;66:663–668.
3. Rahman NM, Maskell NA, Davies CW, Hedley EL, Nunn AJ, Gleeson FV, Davies RJ. The relationship between chest tube size and clinical outcome in pleural infection. *Chest*. 2010;137:536–543.
4. Davies HE, Davies RJ, Davies CW. Management of pleural infection in adults: British Thoracic Society Pleural Disease Guideline 2010. *Thorax*. 2010;65(Suppl 2):ii41–ii53.
5. Hippocrates. *The Genuine Works of Hippocrates.* Whitefish, MT: Kessinger; 2007.
6. Cameron R, Davies HR. Intrapleural fibrinolytic therapy versus conservative management in the treatment of adult parapneumonic effusions and empyema. *Cochrane Database Syst Rev.* 2008;2:CD002312.
7. Christie NA. Management of pleural space: effusions and empyema. *Surg Clin North Am*. 2010;90:919–934.
8. Rahman NM, Chapman SJ, Davies RJ. The approach to the patient with a parapneumonic effusion. *Clin Chest Med*. 2006;27:253–266.
9. Davies HE, Lee YCG. Pleural effusion, empyema and pneumothorax. In: Albert SS, Jett JR, eds. *Clinical Respiratory Medicine*. 3rd ed. Philadelphia, PA: Mosby Elsevier 2008:853–868.
10. Shields TW. Anatomy of the pleura. In: Shields TW, LoCicero, J, Reed, CE, Feins, RH, eds. *General Thoracic Surgery.* Philadelphia, PA: Lippincott Williams & Wilkins 2005:729–733.
11. Light RW. Physiology of pleural fluid production. In: Shields H, LoCicero, J, Reed, CE, Feins RH, eds. *General Thoracic Surgery*. 7th ed. Philadelphia, PA: Lippincott Williams & Wilkins 2005:763–769.
12. Kocijancic I, Kocijancic K, Cufer T. Imaging of pleural fluid in healthy individuals. *Clin Radiol*. 2004;59:826–829.
13. Delvaeye M, Conway EM. Coagulation and innate immune responses: can we view them separately? *Blood*. 2009;114:2367–2374.
14. Finigan JH. The coagulation system and pulmonary endothelial function in acute lung injury. *Microvasc Res*. 2009;77:35–38.
15. Massberg S, Grahl L, von Bruehl ML, Manukyan D, Pfeiler S, Goosmann C, Brinkmann V, Lorenz M, Bidzhekov K, Khandagale AB, et al. Reciprocal coupling of coagulation and innate immunity via neutrophil serine proteases. *Nat Med*. 2010;16:887–896.
16. Koegelenberg CFN, Diacon AH, Bolliger CT. Parapneumonic pleural effusion and empyema. *Respiration*. 2008;75:241–250.
17. Cremonesini D, Thomson AH. How should we manage empyema: antibiotics alone, fibrinolytics, or primary video-assisted thoracoscopic surgery (VATS)? *Semin Respir Crit Care Med*. 2007;28:322–332.
18. Gates RL, Caniano DA, Hayes JR, Arca MJ. Does VATS provide optimal treatment of empyema in children? A systematic review. *J Pediatr Surg*. 2004;39:381–386.
19. Kurian J, Levin TL, Han BK, Taragin BH, Weinstein S. Comparison of ultrasound and CT in the evaluation of pneumonia complicated by parapneumonic effusion in children. *AJR Am J Roentgenol.* 2009;193:1648–1654.
20. Strachan RE, Jaffe A. Recommendations for managing pediatric empyema thoracis. *Med J Austr.* 2011;195:95.
21. Brixey AG, Luo Y, Skouras V, Awdankiewicz A, Light RW. The efficacy of chest radiographs in detecting parapneumonic effusions. *Respirology.* 2011;16:1000–1004.
22. Eibenberger KL, Dock WI, Ammann ME, Dorffner R, Hormann MF, Grabenwoger F. Quantification of pleural effusions: sonography versus radiography. *Radiology.* 1994;191:681–684.
23. Heffner JE, Klein JS, Hampson C. Diagnostic utility and clinical application of imaging for pleural space infections. *Chest*. 2010;137:467–479.
24. Kocijancic I, Vidmar K, Ivanovi-Herceg Z. Chest sonography versus lateral decubitus radiography in the diagnosis of small pleural effusions. *J Clin Ultrasound*. 2003;31:69–74.
25. Vignon P, Chastagner C, Berkane V, Chardac E, Francois B, Normand S, Bonnivard M, Clavel M, Pichon N, Preux PM, et al. Quantitative assessment of pleural effusion in critically ill patients by means of ultrasonography. *Crit Care Med*. 2005;33:1757–1763.
26. Light RW, Girard WM, Jenkinson SG, George RB. Parapneumonic effusions. *Am J Med*. 1980;69:507–512.
27. Kocijancic I, Tercelj M, Vidmar K, Jereb M. The value of inspiratory-expiratory lateral decubitus views in the diagnosis of small pleural effusions. *Clin Radiol*. 1999;54:595–597.
28. Sahn SA, Light RW. The sun should never set on a parapneumonic effusion. *Chest*. 1989;95:945–947.
29. Light RW. Clinical practice. Pleural effusion. *N Engl J Med*. 2002;346: 1971–1977.
30. Colice GL, Curtis A, Deslauriers J, Heffner J, Light R, Littenberg B, Sahn S, Weinstein RA, Yusen RD. Medical and surgical treatment of parapneumonic effusions: an evidence-based guideline. *Chest*. 2000;118:1158–1171.
31. Heffner JE, Brown LK, Barbieri C, DeLeo JM. Pleural fluid chemical analysis in parapneumonic effusions. A meta-analysis. *Am J Respir Crit Care Med*. 1995;151:1700–1708.
32. Light RW, MacGregor MI, Ball WC Jr, Luchsinger PC. Diagnostic significance of pleural fluid pH and PCO2. *Chest*. 1973;64:591–596.
33. Porcel JM. Pleural fluid tests to identify complicated parapneumonic effusions. *Curr Opin Pulmonol Med*. 2010;16:357–361.
34. Potts DE, Levin DC, Sahn SA. Pleural fluid pH in parapneumonic effusions. *Chest*. 1976;70:328–331.
35. Fysh ET, Smith NA, Lee YC. Optimal chest drain size: the rise of the small-bore pleural catheter. *Semin Respir Crit Care Med*. 2010;31:760–768.
36. Light RW. Pleural controversy: optimal chest tube size for drainage. *Respirology.* 2011;16:244–248.
37. American College of Surgeons Committee on Trauma. *Advanced Trauma Life Support for Doctors*. 8th ed. Chicago, IL: American College of Surgeons; 2008:108.
38. Chen KY, Hsueh PR, Liaw YS, Yang PC, Luh KT. A 10-year experience with bacteriology of acute thoracic empyema: emphasis on *Klebsiella pneumoniae* in patients with diabetes mellitus. *Chest*. 2000;117:1685–1689.
39. Falguera M, Carratala J, Bielsa S, Garcia-Vidal C, Ruiz-Gonzalez A, Chica I, Gudiol F, Porcel JM. Predictive factors, microbiology and outcome of patients with parapneumonic effusion. *Eur Respir J.* 2011;38:1173–1179.
40. Maskell NA, Batt S, Hedley EL, Davies CW, Gillespie SH, Davies RJ. The bacteriology of pleural infection by genetic and standard methods and its mortality significance. *Am J Respir Crit Care Med*. 2006;174: 817–823.
41. Maskell NA, Davies CW, Nunn AJ, Hedley EL, Gleeson FV, Miller R, Gabe R, Rees GL, Peto TE, Woodhead MA, et al. U.K. Controlled trial of intrapleural streptokinase for pleural infection. *N Engl J Med*. 2005;352:865–874.
42. Meyer CN, Rosenlund S, Nielsen J, Friis-Moller A. Bacteriological etiology and antimicrobial treatment of pleural empyema. *Scand J Infect Dis*. 2011;43:165–169.
43. Porta G, Rodriguez-Carballeira M, Gomez L, Salavert M, Freixas N, Xercavins M, Garau J. Thoracic infection caused by *Streptococcus milleri*. *Eur Respir J.* 1998;12:357–362.
44. Ripley RT, Cothren CC, Moore EE, Long J, Johnson JL, Haenel JB. *Streptococcus milleri* infections of the pleural space: operative management predominates. *Am J Surg*. 2006;192:817–821.
45. Vaudaux P, Waldvogel FA. Gentamicin inactivation in purulent exudates: role of cell lysis. *J Infect Dis*. 1980;142:586–593.
46. Sahn SA. Diagnosis and management of parapneumonic effusions and empyema. *Clin Infect Dis*. 2007;45:1480–1486.
47. Tillett WS, Sherry S. The effect in patients of streptococcal fibrinolysin and streptococcal desoxyribonuclease on fibrinous, purulen, and sanguinous pleural exudations. *J Clin Invest*. 1949;28:173–190.
48. Davies RJ, Traill ZC, Gleeson FV. Randomised controlled trial of intrapleural streptokinase in community-acquired pleural infection. *Thorax*. 1997;52:416–421.
49. Bouros D, Schiza S, Patsourakis G, Chalkiadakis G, Panagou P, Siafakas NM. Intrapleural streptokinase versus urokinase in the treatment of complicated parapneumonic effusions: a prospective, double-blind study. *Am J Respir Crit Care Med*. 1997;155:291–295.
50. Bouros D, Schiza S, Tzanakis N, Chalkiadakis G, Drositis J, Siafakas N. Intrapleural urokinase versus normal saline in the treatment of complicated parapneumonic effusions and empyema. A randomized, double-blind study. *Am J Respir Crit Care Med*. 1999;159:37–42.
51. Tuncozgue B, Ustunsoy H, Sirikoz C. Intrapleural urokinase in the management of parapneumonic empyema: a randomized controlled trial. *Int J Clin Pract*. 2001;55:658–660.
52. Heffner JE. Multicenter trials of treatment for empyema—after all these years. *N Engl J Med*. 2005;352:926–928.

© 2012 Lippincott Williams & Wilkins

Copyright © 2012 Lippincott Williams & Wilkins. Unauthorized reproduction of this article is prohibited.

53. Gervais DA, Levis DA, Hahn PF, Uppot RN, Arellano RS, Mueller PR. Adjunctive intrapleural tissue plasminogen activator administered via chest tubes placed with imaging guidance: effectiveness and risk for hemorrhage. *Radiology.* 2008;246:956–963.
54. Simpson G, Roomes D, Heron M. Effects of streptokinase and deoxyribonuclease on viscosity of human surgical and empyema pus. *Chest*. 2000;117:1728–1733.
55. Sherry S, tillett WS, Christensen LR. Presence and significance of desoxyribose nucleoprotein in the purulent pleural exudates of patients. *Proc Soc Exp Biol Med*. 1948;68:179–184.
56. Rahman NM, Maskell NA, West A, Teoh R, Arnold A, Mackinlay C, Peckham D, Davies CW, Ali N, Kinnear W, et al. Intrapleural use of tissue plasminogen activator and DNase in pleural infection. *N Engl J Med*. 2011;365:518–526.
57. Mergo PJ, Helmberger T, Didovic J, Cernigliaro J, Ros PR, Staab EV. New formula for quantification of pleural effusions from computed tomography. *J Thorac Imaging*. 1999;14:122–125.
58. Lee SF, Lawrence D, Booth H, Morris-Jones S, Macrae B, Zumla A. Thoracic empyema: current opinions in medical and surgical management. *Curr Opin Pulm Med*. 2010;16:194–200.
59. Zahid I, Nagendran M, Routledge T, Scarci M. Comparison of video-assisted thoracoscopic surgery and open surgery in the management of primary empyema. *Curr Opin Pulmonol Med*. 2011;17:255–259.
60. Katlic MR, Facktor MA. Video-assisted thoracic surgery utilizing local anesthesia and sedation: 384 consecutive cases. *Ann Thorac Surg*. 2010;90:240–245.
61. Yim A, Shioe, ADL. Video-assisted thoracic surgery as a diagnostic tool. In: Shields TW, Locicero J, Reed CE, Feins RH, eds. *General Thoracic Surgery.* Philadelphia, PA: Lippincott; 2005:313–323.
62. Deslauriers J, Jacques LF, Gregoire J. Role of Eloesser flap and thoracoplasty in the third millennium. *Chest Surg Clin North Am*. 2002;12:605–623.
63. Haghshenasskashani A, Rahnavardi M, Yan TD, McCaughan BC. Intrathoracic application of a vacuum-assisted closure device in managing pleural space infection after lung resection: is it an option? *Interact Cardiovasc Thorac Surg*. 2011;13:168–174.
64. Palman M, Van Breugel HN, Gesgkes GG, Van Belle A, Swennen JM, Drijkoningen AH, Van der Hulst RR, Maessen JG. Open window thoracostomy treatment of empyema is accelerated by vacuum-assisted closue. *Ann Thorac Surg*. 2009;88:1131–1136.
65. Sziklavari Z, Grosser C, Neu R, Schemm R, Kortner A, Szoke T, Hofmann H-S. Complex pleural empyema can be safely treated with vacuum-assisted closure. *Cardiothorac Surg*. 2011;6:130–138.
66. Schreiner W, Fuchs P, Autschbach R, Pallua N, Sirbu H. Modified technique for thoracomyoplasty after posterolateral thoracotomy. *Thorac Cardiovasc Surg*. 2010;58:98–101.
67. Walsh MD, Bruno AD, Onaitis MW, Erdmann D, Wolfe WG, Toloza EM, Levin LS. The role of intrathoracic free flaps for chronic empyema. *Ann Thorac Surg*. 2011;91:865–868.

Copyright © 2012 Lippincott Williams & Wilkins. Unauthorized reproduction of this article is prohibited.