

Adult blunt hepatic injury: A Western Trauma Association critical decisions algorithm

Natasha Keric, MD, FACS, David V. Shatz, MD, Morgan Schellenberg, MD, MPH, Marc de Moya, MD, Laura J. Moore, MD, Carlos V.R. Brown, MD, Jennifer L. Hartwell, MD, Kenji Inaba, MD, Eric J. Ley, MD, Kimberly A. Peck, MD, Charles J. Fox, MD, Nelson G. Rosen, MD, Jordan A. Weinberg, MD, Raul Coimbra, MD, PhD, Rosemary Kozar, MD, and Matthew J. Martin, MD, Phoenix, Arizona

This is a recommended evaluation and management algorithm from the Western Trauma Association (WTA) Algorithms Committee addressing the management of adult patients with blunt hepatic injury. Because there is a paucity of published prospective randomized clinical trials that have generated class I data, these recommendations are based primarily on published prospective and retrospective cohort studies, as well as expert opinion of the WTA members. The final algorithm is the result of an iterative process including an initial internal review and revision by the WTA Algorithm Committee members, followed by final revisions based on input during and after presentation of the algorithm to the full WTA membership.

The liver continues to be one of the most frequently injured solid organs in blunt abdominal trauma.¹ The WTA Algorithms Committee's last published guidelines were on the nonoperative management of adult blunt hepatic trauma in 2009² and operative management in 2011.³ With emphasis on selective operative and nonoperative management of blunt hepatic injuries, recent literature

has sought to reexamine the outcomes of nonoperative interventions and improve techniques and adjuncts for operative management.⁴ The intent of this article is to provide an updated WTA practice management guideline for the diagnosis and management of adult blunt hepatic injuries, with additional guidance on the subsequent inpatient management decisions such as admission location, initiation of diet and ambulation, and other common issues.

The algorithm (Fig. 1), management guidelines (Table 1), and accompanying comments represent a safe and sensible approach to the evaluation of the adult patient with blunt hepatic injury. We recognize that there will be multiple factors that may warrant or require deviation from any single recommended algorithm and that no algorithm can completely replace expert bedside clinical judgment. We encourage institutions to use this as a general framework in the approach to these patients and to customize and adapt the algorithm to better suit their specific resources and requirements.

Submitted: June 28, 2023, Revised: August 29, 2023, Accepted: September 5, 2023, Published online: September 25, 2023.

From the Division of Trauma, Surgical Critical Care and Acute Care Surgery, Department of Surgery (N.K.), Banner University Medical Center, Phoenix, Arizona; University of California (D.V.S.), Davis, Sacramento, California; Division of Acute Care Surgery, Department of Surgery, University of Southern California (M.S., K.I., M.J.M.), Los Angeles, California; Division of Acute Care Surgery, Department of Surgery, Medical College of Wisconsin (M.d.M.), Milwaukee, Wisconsin; Division of Acute Care Surgery, Department of Surgery, University of Texas—Houston Medical Center (L.J.M.), Houston, Texas; Division of Acute Care Surgery, Department of Surgery, Dell Medical School (C.V.R.B.), University of Texas at Austin, Austin, Texas; Division of Acute Care Surgery, Department of Surgery, University of Kansas Medical Center (J.L.H.), Kansas City, Kansas; Division of Acute Care Surgery, Department of Surgery, Cedars-Sinai Medical Center (E.J.L.), Los Angeles, California; Scripps Mercy Hospital (K.A.P.), San Diego, California; Division of Vascular Surgery, Department of Surgery, R Adams Cowley Shock Trauma Center (C.J.F., R.K.), Baltimore, Maryland; Division of Pediatric General and Thoracic Surgery, Children's Hospital (N.G.R.), Cincinnati, Ohio; Division of Acute Care Surgery, Department of Surgery, St. Joseph's Medical Center (J.A.W.), Phoenix, Arizona; and Riverside University Health System Medical Center (R.C.), Riverside, California.

This study was presented at the 52nd Annual Meeting of the Western Trauma Association, March 5–10, 2023, in Lake Louise, Alberta, Canada.

Supplemental digital content is available for this article. Direct URL citations appear in the printed text, and links to the digital files are provided in the HTML text of this article on the journal's Web site (www.jtrauma.com).

Address for correspondence: Natasha Keric, MD, FACS, Division of Trauma, Surgical Critical Care and Acute Care Surgery, Department of Surgery, Banner University Medical Center, 1411 N 12th St, First Floor, Phoenix, AZ 85006; email: natasha.keric@bannerhealth.com.

DOI: 10.1097/TA.0000000000004141

J Trauma Acute Care Surg
Volume 96, Number 1

ALGORITHM

The following lettered sections correspond to the letters identifying specific sections of the algorithm shown in Figure 1. In each section, we have provided a summary of the important aspects and options that should be considered at that point in the evaluation and management process. Table 2 references the lettered sections in the algorithm in Figure 1 and summarizes the gaps identified in current literature.

A. Initial Assessment

Initial evaluation of all adult patients with blunt abdominal injury should follow the principles outlined in Advanced Trauma Life Support.⁵ If there is peritonitis or evisceration on physical examination, the patient should be taken emergently to the operating room for an exploratory laparotomy. Unstable patients should undergo continued resuscitation and rapid evaluation to determine the source of hemodynamic instability. In the unstable patient, with signs on physical examination of intra-abdominal hemorrhage or a positive Focused Assessment with Sonography in Trauma (FAST) examination, immediate laparotomy is warranted. An equivocal or negative FAST examination should prompt ongoing evaluation for hemorrhage with either a repeat FAST examination or a diagnostic peritoneal aspiration (DPA), which has utility in unstable blunt trauma patients with no other

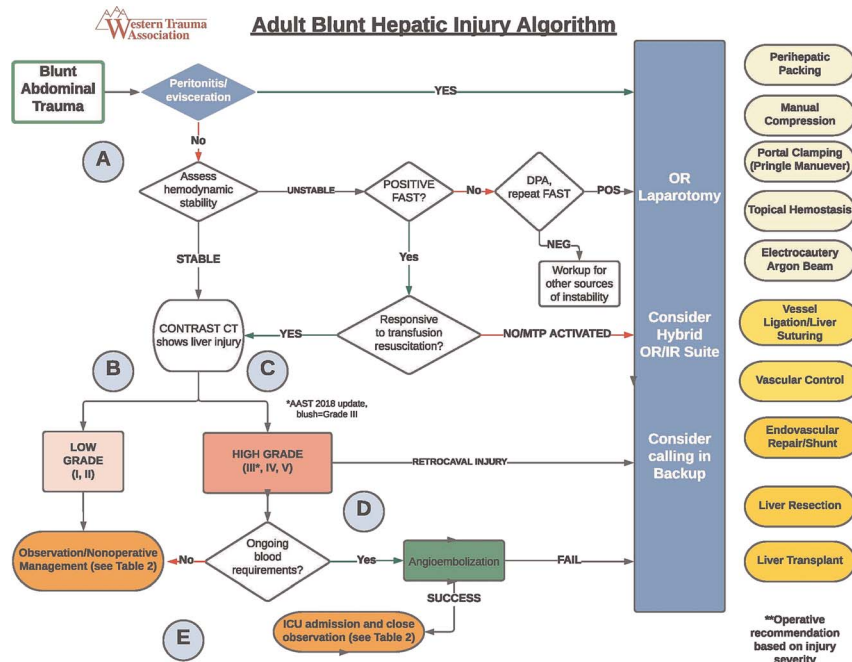


Figure 1. Western Trauma Association algorithm for the diagnosis and management of blunt hepatic injury in adults. Circled letters correspond to lettered sections in the article's text. OR, operating room; IR, interventional radiology.

obvious sources of instability.⁶ Patients who have a positive FAST examination or DPA and who remain unstable despite aggressive blood product resuscitation should also go emergently to the operating room. If a repeat FAST examination or DPA is negative, workup for other sources of hemodynamic instability should continue. Computed tomography (CT) imaging after an

emergent operative intervention could help identify additional injuries, even if they might not warrant subsequent interventions.^{7,8} Patients with a positive FAST examination who are responding to blood transfusion resuscitation using contemporary hemodynamic monitoring and end points of resuscitation⁹ should undergo contrast-enhanced CT imaging.

TABLE 1. Blunt Hepatic Injury Guideline for Nonoperative and Postintervention Management

AAST Grade	Low Grade	High Grade
	I and II	III, IV, and V
ICU	No	Yes — 24 h minimum*
Laboratories (CBC)	Every 12 h until stable × 2	Every 6 h until stable × 2
Monitoring	Vital signs every 4 h	Vital signs every 1 h Continuous heart rate with every 2-h BP check
Diet	Diet ad lib as tolerated Clear liquid diet for 12 h	NPO × 12 h
VTE prophylaxis	Start within 24 h of stable Hgb	Start within 24–48 h of stable Hgb
Follow-up contrast CT scan	Clinical change (sepsis, abdominal pain, jaundice) Laboratory change (elevated transaminases or decrease in Hgb)	Clinical change (sepsis, abdominal pain, jaundice) Laboratory change (elevated transaminases or decrease in Hgb) Consider screening CT at 3–5 d before discharge to evaluate for PSA, AVF, biliary issues
Biloma/bile leak	ERCP/IR	ERCP/IR Surgical management if recurrent, failure of nonoperative management
Abscess	Drain/IR Surgical management if recurrent, failure of nonoperative management	Drain/IR Surgical management if recurrent, failure of nonoperative management
Discharge criteria (minimum admission time)	Stable Hgb 24 h from injury Tolerating oral intake	Stable Hgb 72 h from injury Tolerating oral intake
Return to normal activity	Grade + 2 = weeks to return	6 wk and clinical clearance by MD

*Select high-grade injuries without evidence of hemorrhage may not require ICU admission.

AVF, arteriovenous fistula; BP, Blood Pressure; CBC, Complete Blood Count; ERCP, Endoscopic Retrograde Cholangiopancreatography; Hb, Hemoglobin; IR, Interventional Radiology; NPO, Nothing by mouth; MD, Medical Doctor; PSA, pseudoaneurysm; VTE, Venous Thromboembolism.

TABLE 2. Identified Research Gaps in Hepatic Trauma

Subject/Knowledge Deficit	Algorithm Section
1. No established consensus on how much blood loss or transfusion requirement mandates the decision to intervene operatively or angiographically	A
2. No consensus guidelines on appropriate patient selection criteria for those who would benefit from angioembolization	C
3. Limited availability of high-quality randomized controlled trials on failure of nonoperative management	D
4. Identification of risk factors that lead to hepatic complications post angioembolization	D
5. Follow-up screening protocol with contrast CT for pseudoaneurysm diagnosis	E
6. No standard monitoring protocols and follow-up care for nonoperative and post intervention management	E

B. Management of Low-Grade Liver Injuries (AAST Grades I and II)

In hemodynamically normal patients with low-grade liver injuries and no other injuries requiring operative intervention, observation and nonoperative management are the treatment of choice. Patients with low-grade injuries generally do not require intensive care unit (ICU) admission and should undergo serial clinical evaluation and scheduled or on-demand hematocrit testing for at least 24 hours (Table 1).

C. Management of High-Grade Liver Injuries (AAST Grades III, IV, and V)

The revised Organ Injury Scale for liver injury in 2018 incorporated CT-diagnosed vascular injury (contrast blush, pseudoaneurysm, or arteriovenous fistula) to the existing imaging criteria. Any injury, in the presence of a liver vascular injury or active bleeding in the liver parenchyma, is defined as at least an American Association for the Surgery of Trauma Grade III injury.¹⁰ An injury with active bleeding extending beyond the liver parenchyma into the peritoneum is considered a Grade IV injury. Patients who are severely injured with a high-grade liver injury and have hemodynamic instability after initial resuscitation (transient responders) would benefit from being in a hybrid operating suite with both major operative and interventional radiology capabilities.¹¹

A detailed description of operative management of hepatic injuries is beyond the scope of this article; however, key principles are addressed. Simple maneuvers to control bleeding should first be used, such as perihepatic packing and manual compression.¹² If packing fails to control the bleeding, the next step is the Pringle maneuver, which can help identify the anatomic injury. Bleeding that is controlled with the clamping of the porta hepatis is likely coming from the parenchyma, and hemorrhage can be controlled with electrocautery or argon beam coagulator, or vessel ligation with sutures or staplers.^{1,12} If bleeding continues despite portal triad clamping, it is likely arising from the hepatic veins, which need to be ligated, or from the retrohepatic inferior vena cava.¹² At any point, the surgeon should consider calling an experienced colleague for intraoperative assistance and/or intraoperative consultation with a hepatobiliary

specialist surgeon. Injury to the hilar structures, severe fractures, or total hepatic avulsion may require liver resection, portocaval shunt, or, in rare extreme circumstances, a liver transplant.^{1,12} Transfer to a transplant center should be considered if there are no available resources in the face of a devastating liver injury.

Patients who have sustained a high-grade liver injury and have responded to initial resuscitation may be considered for nonoperative management in select settings with availability of resources such as angiography.^{1,13} The role of angioembolization in the management of blunt hepatic injury continues to be controversial and nuanced. Recent literature suggests that the use of angioembolization in severe hepatic injuries is associated with decreased mortality, especially for patients who also undergo an exploratory laparotomy.¹⁴ Complications after angioembolization are not insignificant, and there is still no consensus on whether all injuries with a “contrast blush” (free extravasation of contrast suggesting active hemorrhage) need immediate angiographic embolization.^{4,13} Most experts agree that angioembolization is indicated for hepatic trauma as an adjunct to nonoperative management in hemodynamically stable patients with evidence of ongoing hemorrhage.^{1,13,15} Patients with high-grade liver injuries should be admitted to the ICU for continued observation.

D. Nonoperative Management

Most patients, including those with a high-grade blunt hepatic injury and hemodynamic stability can be managed successfully with nonoperative management.^{1,13,16} A recent systematic review reports failure rates of nonoperative management up to 9.5%.¹⁷ Hemodynamic instability, missed associated intra-abdominal injuries, and presence of peritoneal signs have been found to be significant risk factors for failure of nonoperative management.^{1,13,17} Many studies have reported a higher risk for failure of nonoperative management in high grade injuries, but to date, data are lacking to support grade of injury as an independent risk factor.¹⁷ Despite an improvement in mortality with modern management, morbidity rates of more than 50% have been reported with high-grade liver injuries.¹⁶ Potential complications of nonoperative management include delayed hemorrhage, bile leaks, hemobilia, bile peritonitis, bilious ascites, hemoperitoneum, hepatic abscess, and hepatic necrosis.^{13,16,17} Hepatic bleeding tends to occur early, and although the incidence of delayed hemorrhage is low, it continues to be the most common complication and cause of mortality in nonoperative management.^{13,16}

Complications After Nonoperative Management

Angioembolization has become the mainstay of hemorrhage control in patients who are hemodynamically stable with reported efficacy rates of 83%.¹³ Rebleeding after initial successful embolization has been reported to occur in 5% to 12% of cases.^{15,18} The majority of these rebleeding episodes occur within the first 24 to 48 hours postangioembolization, and thus, careful observation and monitoring during this timeframe are essential.

The incidence of hepatic complications after angioembolization is 40% to 70%.¹⁹ One of the more common complications is hepatic necrosis, with risk up to 43%.^{15,16,18,19} One study has found major hepatic necrosis in up to 63% of patients who underwent embolization, which correlated with grade of

liver injury. Several other studies have also demonstrated hepatic necrosis rates increasing with higher grades of injury.^{19–21}

Biliary complications can occur in up to 22% of patients after angioembolization. However, such complications are not always specific to angioembolization and can occur in up to 30% in patients with hepatic trauma managed without embolization, either operative or nonoperative.^{1,16,18,19} Biliary complications develop later (mean of 12 days post injury) and can generally be managed nonoperatively with endoscopic retrograde cholangiopancreatography, percutaneous drainage, and endobiliary stents.^{1,16} Bile peritonitis may require operative washout and drainage, which can be achieved laparoscopically or via laparotomy.¹

Development of a hepatic abscess in the setting of nonoperative management is rare with reported rates of up to 7%; however, significantly higher rates up to 22% have been reported after angioembolization.^{1,16,19} Perihepatic abscesses are usually successfully managed by image-guided percutaneous drainage.¹ Risk factors contributing to hepatic complications after angioembolization are multifactorial and difficult to define given the lack of a randomized control study.^{15,19}

E. Post Admission Management

There is a paucity in the literature regarding the specific details of postinjury management including the duration of observation, need for serial abdominal examinations, frequency of laboratory measurements, timing to initiate feeding, required period of bed rest, and use of chemical VTE prophylaxis (Fig. 1 and Table 1).^{1,13,15} As a result, recommendations listed in Table 1 represent current literature and the expert consensus of the WTA committee members.

ICU Admission

Multiple studies have shown that nonoperative management of liver injuries, regardless of grade, is safe and successful in >85% of patients.^{13,22} Patients who sustain a high-grade liver injury warrant a period of observation in the ICU, as delayed hemorrhage tends to occur within the first 3 days, with a majority in <24 hours.¹⁶ The ideal setting for this monitoring will vary between centers, but we recommend ICU admission in high-grade injuries and particularly in those who have undergone angioembolization for active hemorrhage. Low-grade injuries do not require routine ICU admission unless there are other patient factors or associated injuries that require ICU admission. Select high-grade liver injuries with no evidence of active hemorrhage may not require ICU admission, although bleeding risk tends to increase with higher grades.¹⁶ The decision for ICU admission will also depend on the specifics of each institution including the nurse staffing levels, trauma team size and composition, ability to perform careful serial examinations, and local experience with major blunt solid organ injuries.

Monitoring/Laboratories

Hemodynamic instability has been identified as a significant risk factor for failure of nonoperative management.²³ Patients who sustain a liver injury warrant monitoring of vital signs, every 4 hours for low-grade injuries and every hour for high-grade injuries, for at least 24 hours. Although there have

not been high quality data to support the link of lower hemoglobin levels and failure of nonoperative management, obtaining serial hematocrit levels until stable is recommended.^{1,13,22,24}

Diet

There is a plethora of literature in support of early enteral feeding in the absence of shock. Several studies have looked at the benefits of improved clinical outcomes with early enteral nutrition after abdominal trauma.²⁵ Recommendations are to initiate a diet early for patients who have a low-grade liver injury and after 12 hours in patients with a high-grade liver who do not exhibit signs of shock or postinjury complications.

Mobility

Prolonged bedrest in patients with blunt solid organ injury has been challenged in the pediatric trauma literature. Despite the concern for delayed hemorrhage, early mobilization in patients undergoing nonoperative management is safe and does not increase the complication rate in patients who are hemodynamically stable, regardless of grade of injury.^{1,26}

Venous Thromboembolism Prophylaxis

Patients with a traumatic injury are at an increased risk for venous thromboembolism and likely benefit from early chemoprophylaxis. Given the risk of delayed hemorrhage in patients who sustain a blunt hepatic injury, there has been some controversy surrounding timing and initiation of chemical thromboprophylaxis. Literature has supported safe initiation of pharmacologic prophylaxis within 48 hours among nonoperatively managed liver injuries in the absence of contraindications, regardless of injury grade,^{1,15,27} although high-grade injuries are understudied.

Follow-up CT Scan

Multiple studies have shown that routine repeat CT imaging without clinical indication is not indicated in patients with hepatic injury.^{16,28,29} Contrast CT imaging to screen for pseudoaneurysms following a high-grade solid organ injury has been slightly more controversial. Hepatic artery pseudoaneurysm is a rare complication after hepatic trauma; however, risk of rupture and life-threatening hemorrhage has prompted many to advocate for routine follow-up screening with contrast CT.³⁰ Despite the associated high morbidity, there has not been routine adoption of a screening protocol to evaluate for delayed pseudoaneurysm diagnosis. Recent literature has shown benefit of delayed contrast imaging in detecting vascular lesions in patients with high-grade blunt hepatic injuries, prompting intervention in up to 17%.^{31,32}

Return to Normal Activity

Recommendations in adults for return to normal activity after blunt solid organ injury has been extrapolated from pediatric literature. The American Pediatric Surgical Association developed recent activity restriction guidelines that recommend injury grade +2 weeks.³³ Adherence to the guideline did not show any difference in rebleeding events but did show a higher risk of readmissions in patients who were nonadherent.³³ We recommend utilization of the American Pediatric Surgical Association activity restriction guidelines as a minimum standard, with

increased duration of restrictions tailored to the individual patient based on their age, comorbidities, type of liver injury, and the risk of their activities or occupation for incurring additional trauma to the abdomen.

OTHER AREAS OF CONTROVERSY

There are several areas of controversies in the management of blunt hepatic injury that lack high-quality evidentiary support and where further focused research is required. Table 2 summarizes the existing research deficits related to this topic that were identified by the authors during algorithm preparation.

SUMMARY

Nonoperative management of blunt hepatic injuries has become the standard of care for patients who are hemodynamically stable. Angioembolization has become a useful adjunct in the success rates of nonoperative management; however, there is much interest in determining its benefit and effectiveness for all identified vascular injuries on imaging. There are still patients who require operative intervention, and careful clinical and laboratory follow-up is paramount in detecting early complications and failure of nonoperative management.

AUTHORSHIP

N.K., D.V.S., M.S., M.d.M., L.J.M., C.V.R.B., J.L.H., K.I., E.J.L., K.A.P., C.J.F., N.G.R., J.A.W., R.C., and M.J.M. contributed in the conception and design. N.K., D.V.S., R.K., and M.J.M. contributed in the acquisition of data. N.K., D.V.S., M.S., M.d.M., L.J.M., C.V.R.B., J.L.H., K.I., E.J.L., C.J.F., N.G.R., J.A.W., and M.J.M. contributed in the analysis and interpretation of data. N.K., D.V.S., and M.J.M. contributed in the drafting of the manuscript. N.K., D.V.S., M.S., C.V.R.B., J.L.H., K.A.P., C.J.F., R.K., and M.J.M. contributed in the critical revision of the manuscript. D.V.S. and M.J.M. contributed in the supervision. All authors have seen and approved the final manuscript as submitted. The first author (N.K.) had full access to all data in the study and takes responsibility for the integrity of the data and the accuracy of the data analysis.

DISCLOSURE

Conflicts of Interest: Author Disclosure forms have been supplied and are provided as Supplemental Digital Content (<http://links.lww.com/TA/D271>).

REFERENCES

- Coccolini F, Coimbra F, Ordonez C. Liver trauma: WSES 2020 guidelines. *World J Surg*. 2020;15:24.
- Kozar RA, Moore FA, Moore EE, West M, Cocanour CS, Davis J, et al. Western Trauma Association critical decisions in trauma: nonoperative Management of Adult Blunt Hepatic Trauma. *J Trauma*. 2009;67:1144–1149.
- Kozar RA, Feliciano DV, Moore EE, Moore FA, Cocanour CS, West MA, et al. Western Trauma Association/critical decisions in trauma: operative management of adult blunt hepatic trauma. *J Trauma*. 2011;71(1):1–5.
- Samuels JM, Carmichael H, McIntyre RC Jr., Urban S, Ballow S, Dirks RC, et al. An observation-first strategy for liver injuries with “blush” on computed tomography is safe and effective. *J Trauma*. 2023;94(2):281–287.
- American College of Surgeons. *Advanced Trauma Life Support*. 2023. Available at: <https://www.facs.org/quality-programs/trauma/education/advanced-trauma-life-support/?page=1>. Accessed March 30, 2023.
- Schellenberg M, Owattanapanich N, Emigh B, Karavites L, Clark D, Lam L, et al. Contemporary utility of diagnostic peritoneal aspiration in trauma. *J Trauma*. 2021;91:814–819.
- Matsushima M, Inaba K, Dollbaum R, Khor D, Jhaveri D, Jimenez O, et al. The role of computed tomography after emergent trauma operation. *J Surg Res*. 2016;206(2):286–291.
- Weis J, Cunningham K, Forsythe RM, Billiar T, Peitzman AB, Sperry JL. The importance of empiric abdominal computed tomography after urgent laparotomy for trauma: do they reveal unexpected injuries? *Surgery*. 2014; 156(4):979–987.
- Martin N, Codner P, Greene W, Brasel K, Michetti C. Contemporary hemodynamic monitoring, fluid responsiveness, volume optimization, and endpoints of resuscitation: an AAST critical care committee clinical consensus. *Trauma Surg Acute Care Open*. 2020;5(1):e000411.
- Kozar RA, Crandall M, Shanmuganathan K, Zarzar B, Coburn M, Cribari C, et al. Organ injury scaling 2018 update: spleen, liver, and kidney. *J Trauma Acute Care Surg*. 2018;85(6):1119–1122.
- Carver D, Kirkpatrick A, D’Amours S, Hameed SM, Beveridge J, Ball C. A prospective evaluation of the utility of a hybrid operating suite for severely injured patients overstated or underutilized? *Ann Surg*. 2020;271:958–961.
- Peitzman AB, Wallis MJ. Advanced operative techniques in the management of complex liver injury. *J Trauma Acute Care Surg*. 2012;73(3):765–770.
- Stassen N, Bhullar I, Cheng J, Crandall ML, Friese RS, Guillaumondegui OD, et al. Nonoperative management of blunt hepatic injury: an eastern Association for the Surgery of Trauma practice management guideline. *J Trauma Acute Care Surg*. 2012;73(5):S288–S293.
- Rozycki GF, Sakran JV, Manukyan MC, Feliciano DV, Radisic A, You B, et al. Angioembolization may improve survival in patients with severe hepatic injuries. *Am Surg*. 2023;31348231157416.
- Cadili A, Gates J. The role of angioembolization in hepatic trauma. *Am Surg*. 2020;87(11):1793–1801.
- Kozar RA, Moore FA, Cothren CC, Moore EE, Sena M, Bulger EM, et al. Risk factors for hepatic morbidity following nonoperative management: multicenter study. *Arch Surg*. 2006;141(5):451–458.
- Boese CK, Hackl M, Müller LP, Ruchholtz S, Frink M, Lechler P. Nonoperative management of blunt hepatic trauma: a systematic review. *J Trauma Acute Care Surg*. 2015;79(4):654–660.
- Green CS, Bulger EM, Kwan SW. Outcomes and complications of angioembolization for hepatic trauma: a systematic review of the literature. *J Trauma Acute Care Surg*. 2016;80(3):529–537.
- Samuels JM, Urban S, Peltz E, Schroepfel T, Heise H, Dorlac WC, et al. A modern, multicenter evaluation of hepatic angioembolization — complications and readmissions persist. *Am J Surg*. 2020;219(1):117–122.
- Dabbs DN, Stein DM, Scalea TM. Major hepatic necrosis: a common complication after angioembolization for treatment of high-grade liver injuries. *J Trauma*. 2009;66(3):621–627.
- Segalini E, Morello A, Leati G, Di Saverio S, Aseni P. Primary angioembolization in liver trauma: major hepatic necrosis as a severe complication of a minimally invasive treatment—a narrative review. *Updates Surg*. 2022;74(5):1511–1519.
- Velmahos GC, Toutouzas K, Radin R, Chan L, Rhee P, Tillou A, et al. High success with nonoperative management of blunt hepatic trauma: the liver is a sturdy organ. *Arch Surg*. 2003;138(5):475–480.
- Polanco PM, Brown JB, Puyana JC, Billiar TR, Peitzman AB, Sperry JL. The swinging pendulum: a national perspective of nonoperative management in severe blunt liver injury. *J Trauma Acute Care Surg*. 2013;75(4): 590–595.
- Hsieh TM, Cheng Tsai T, Liang JL, Che Lin C. Non-operative management attempted for selective high grade blunt hepatosplenic trauma is a feasible strategy. *World J Emerg Surg*. 2014;9(1):51.
- Yin J, Wang J, Zhang S, Yao D, Mao Q, Kong W, et al. Early versus delayed enteral feeding in patients with abdominal trauma: a retrospective cohort study. *Eur J Trauma Emerg Surg*. 2015;41(1):99–105.
- Wang E, Inaba K, Byerly S, Mendelsberg R, Sava J, Benjamin E, et al. Safety of early ambulation following blunt abdominal solid organ injury: a prospective observational study. *Am J Surg*. 2017;214(3):402–406.
- Schellenberg M, Inaba K, Biswas S, Heindel P, Benjamin E, Strumwasser A, et al. When is it safe to start VTE prophylaxis after blunt solid organ injury? A prospective study from a level I trauma center. *World J Surg*. 2019;43(11): 2797–2803.
- Malloum BK, Moore L, Tardif PA, et al. Value of repeat CT for nonoperative management of patients with blunt liver and spleen injury: a systematic review. *Eur J Trauma Emerg Surg*. 2021;47:1753–1761.
- Fletcher KL, Perea LL, Morgan ME, Otaibi BW, Hazelton JP. Repeat imaging in blunt hepatic injuries can wait for clinical change. *J Surg Res*. 2021; 268:119–124.

30. Østerballe L, Helgstrand F, Axelsen T, Hillingsø J, Svendsen LB. Hepatic pseudoaneurysm after traumatic liver injury; is CT follow-up warranted? *J Trauma Manag Outcomes*. 2014;8:18.
31. Schellenberg M, Owattanapanich N, Emigh B, Nichols C, Dilday J, Ugarte C, et al. Pseudoaneurysms after high-grade blunt solid organ injury and the utility of delayed computed tomography angiography. *Eur J Trauma Emerg Surg*. 2022;49:1315–1320.
32. Schellenberg M, Owattanapanich N, Emigh B, Nichols C, Dilday J, Ugarte C, et al. Pseudoaneurysm after high-grade penetrating solid organ injury and the utility of delayed CT angiography. *J Am Coll Surg*. 2023;237:433–438.
33. Notrica DM, Sayers LW, Krishn N, Ostlie DJ, Letton RW, Alder AC, et al. Adherence to APSA activity restriction guidelines and 60-day clinical outcomes for pediatric blunt liver and splenic injuries (BLSI). *J Pediatr Surg*. 2019; 54(2):335–339.