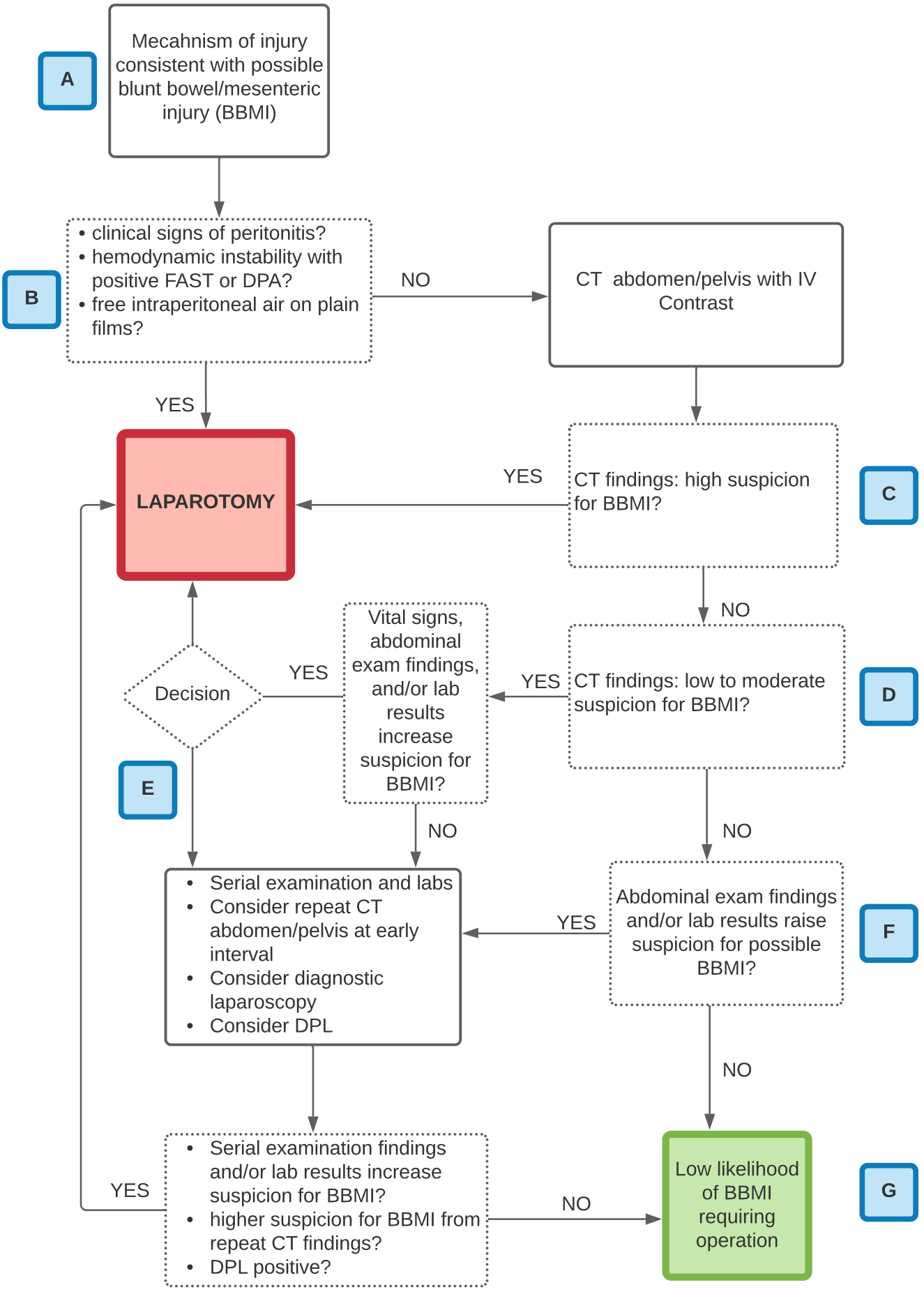
A
Mecahnism of injury consistent with possible blunt bowel/mesenteric injury (BBMI)
B
• clinical signs of peritonitis?
• hemodynamic instability with positive FAST or DPA?
• free intraperitoneal air on plain films?
NO
CT abdomen/pelvis with IV Contrast
YES
LAPAROTOMY
YES
CT findings: high suspicion for BBMI?
C
NO
Vital signs, abdominal exam findings, and/or lab results increase suspicion for BBMI?
YES
Decision
YES
CT findings: low to moderate suspicion for BBMI?
D
E
NO
NO
• Serial examination and labs
• Consider repeat CT abdomen/pelvis at early interval
• Consider diagnostic laparoscopy
• Consider DPL
YES
Abdominal exam findings and/or lab results raise suspicion for possible BBMI?
F
NO
• Serial examination findings and/or lab results increase suspicion for BBMI?
• higher suspicion for BBMI from repeat CT findings?
• DPL positive?
YES
NO
Low likelihood of BBMI requiring operation
G